

Kontrastmittelsonographie am Thorax

Stephan Eisenmann

Martin-Luther-Universität Halle, Abteilung Pneumologie



Martin-Luther-Universität
Halle-Wittenberg

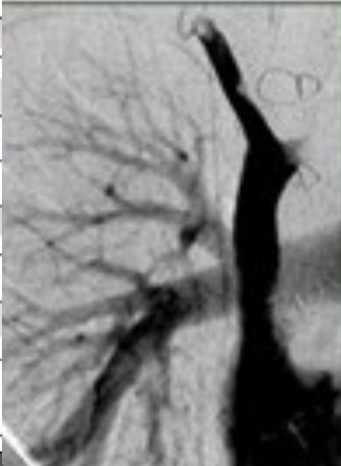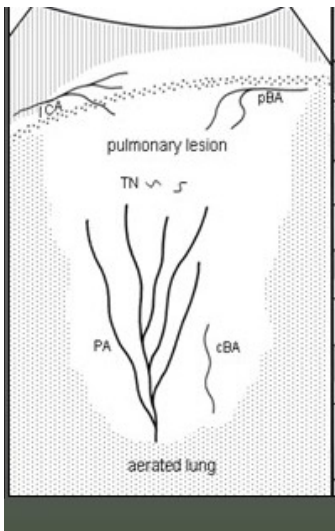


Universitätsklinikum
Halle (Saale)

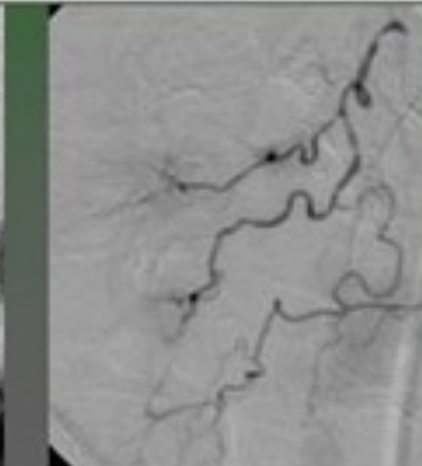
Contrast Enhanced UltraSound = CEUS

Multimodale Durchblutung, dynamische und funktionelle Visualisierung

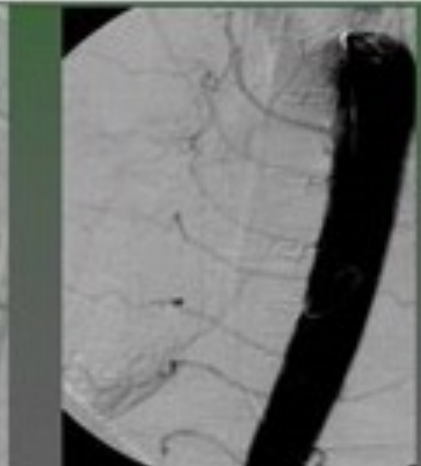
Grenzen bei CEUS wie bei B-Mode-Sonographie



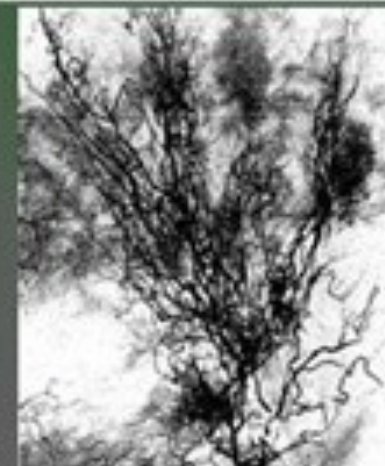
PA



BA



ICA



Tumor



8 μ l Schwefelhexafluorid/ml (= 45 μ g)

Nebenwirkungen: Hautausschlag, Kopfschmerz

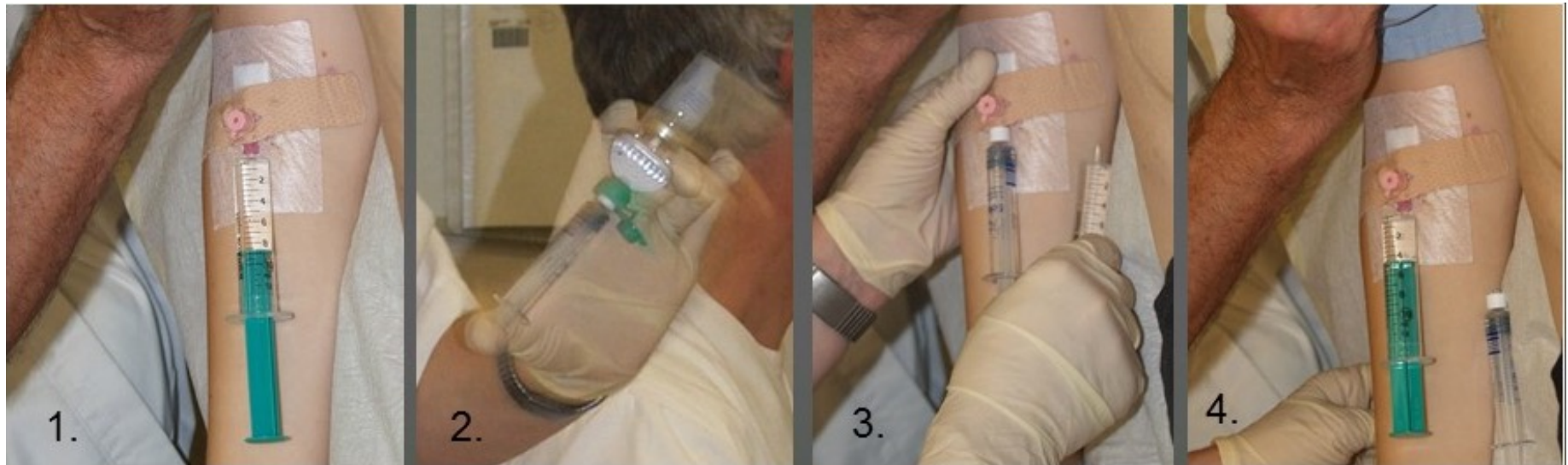
Kontraindikation: STEMI, schwere Herzinsuffizienz, ARDS

! Keine schweren Nebenwirkungen in 23.188 Anwendungen!

Generelle Nebenwirkungsinzidenz: 0.0086%



1. Venöser Zugang 16/18G
2. Kontrastmittel frisch mischen
3. Kontrastmittel injizieren und NaCl-Spülung
4. Beobachtung für 30 min



Niedriger mechanischer Index (< 0.4)

Timer benutzen

Anpassung der Kontrastmittelmenge an das
eigene Gerät (1-4.8 ml)

Übung macht den Meister!

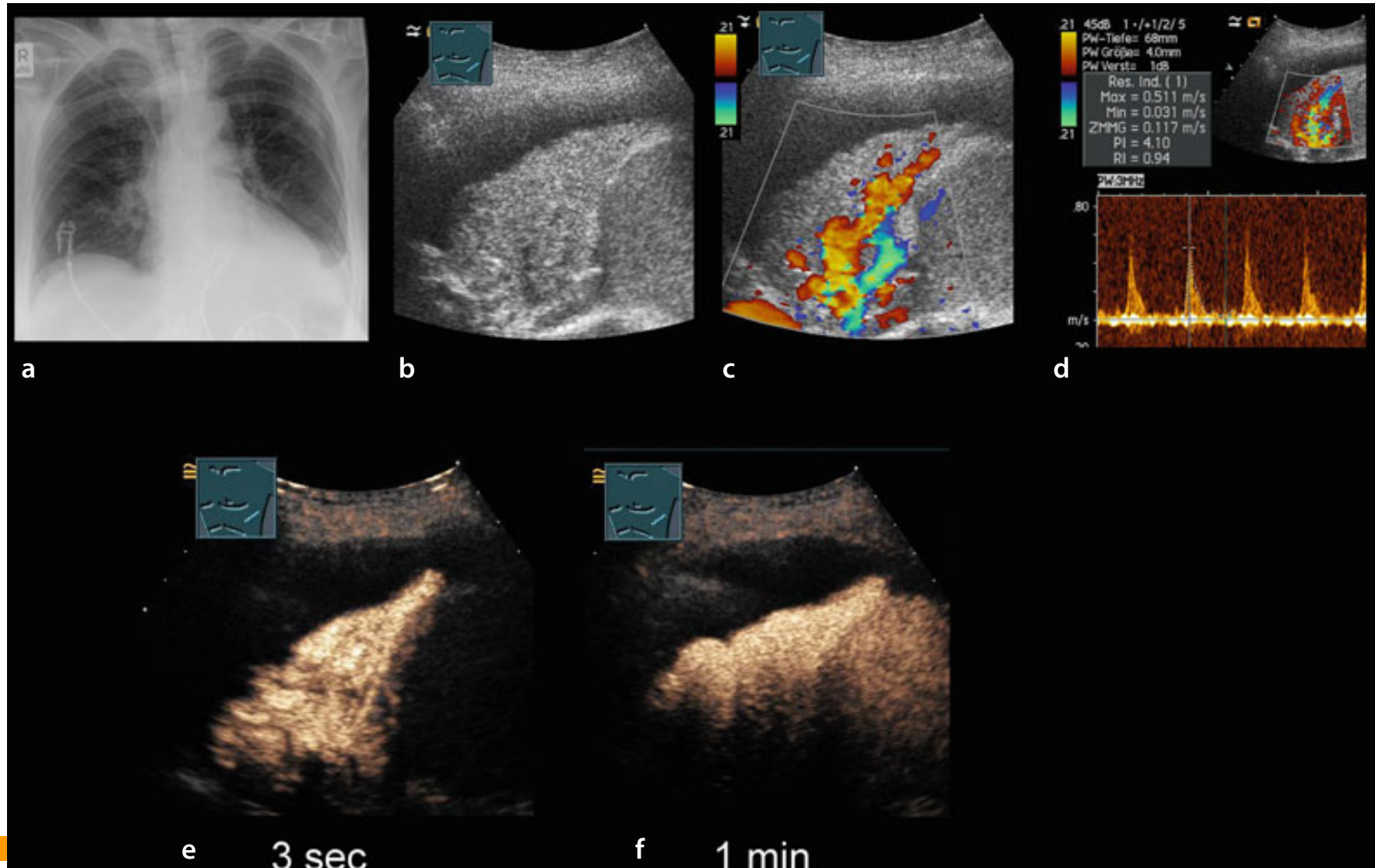


Was kann man mittels CEUS beschreiben?

	Beschreibung	Differentialdiagnose
Time to enhancement	Früh = < 7 sec: PA, centrifugal	Pneumonie
	Spät = > 7 sec: BA, ICA, centripetal	Neovaskularisation (Tumor, Aspergillose, Tbc)
	Parenchymal?	Thoraxwand
Extent of Enhancement	Stark	Inflammation
	Schwach	Tumor
	Fehlend	Embolie, Zyste, Abszess
Quality of Enhancement	Homogen	
	Inhomogen	



PA-Flow: Centrifugal



Mit freundlicher Genehmigung C. Goerg/Marburg

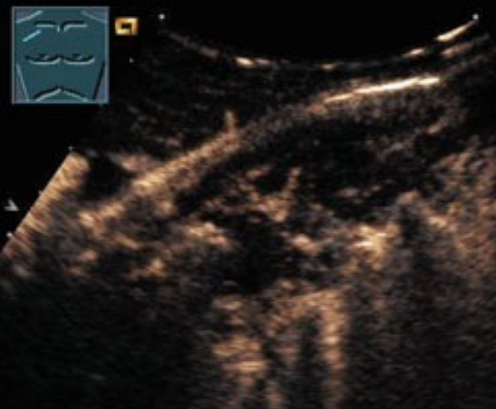
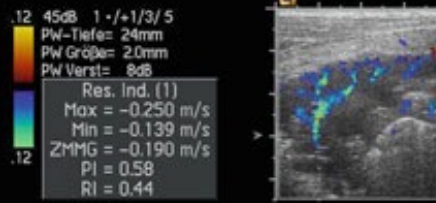
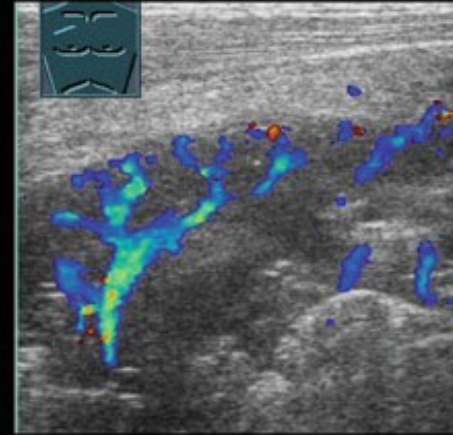
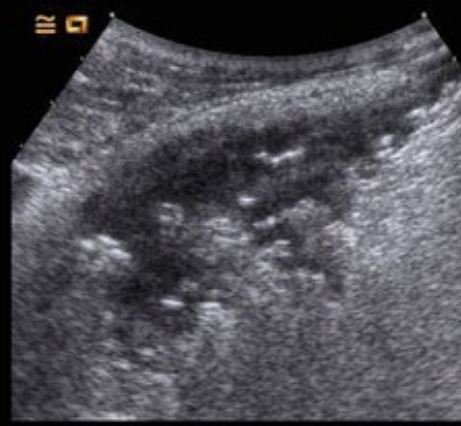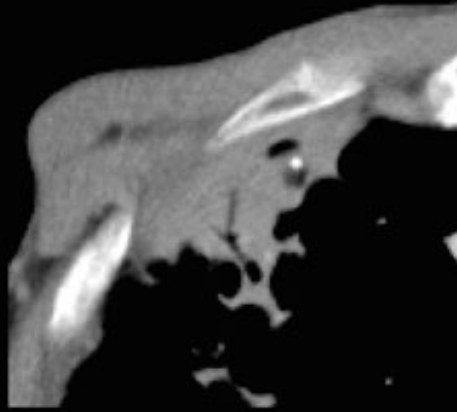

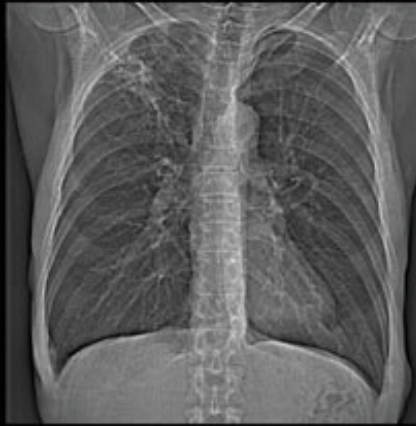
Martin-Luther-Universität
Halle-Wittenberg

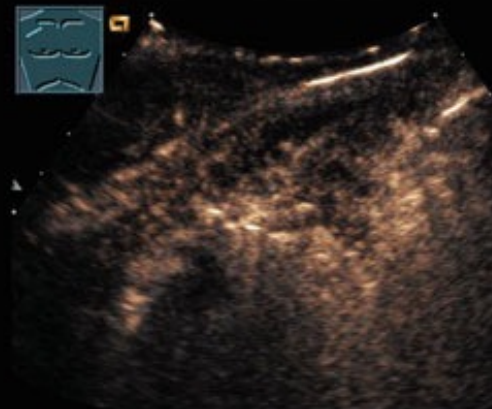


Universitätsklinikum
Halle (Saale)

BA-Flow: Centripetal



21 sec

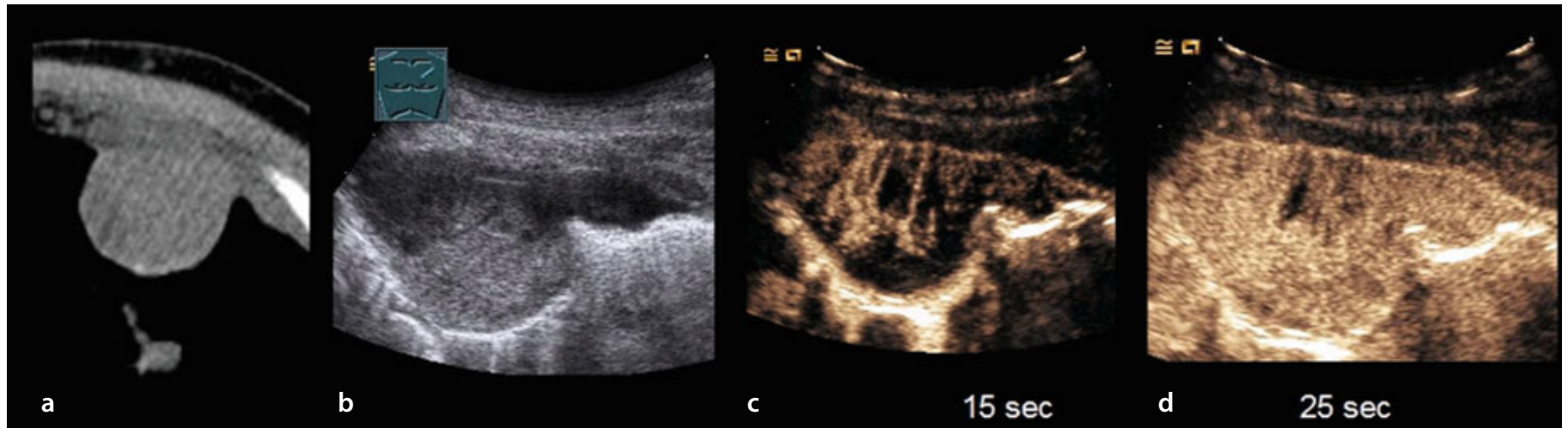


1 min

Mit freundlicher Genehmigung C. Goerg/Marburg

Martin-Luther-Universität
Halle-Wittenberg

Periphere Läsionen – BA/ICA perfusion



Mit freundlicher Genehmigung C. Goerg/Marburg



Martin-Luther-Universität
Halle-Wittenberg



Universitätsklinikum
Halle (Saale)

- Thoraxwandtumore
- Pleuritis periphere Konsolidierung
- Interventionen: Punktionsführung, Drainagemanagement

- Reduktion ionisiertes Kontrastmittel, patientenfreundlich (US vs. CT)



LAE: additives Tool in erfahrener Hand

Lung Cancer: additives Tool bei Biopsie

Lymphknoten: experimental

EBUS: No data

Kinder: Zusatznutzen in Pneumonie und Drainage

Guidelines & Recommendations

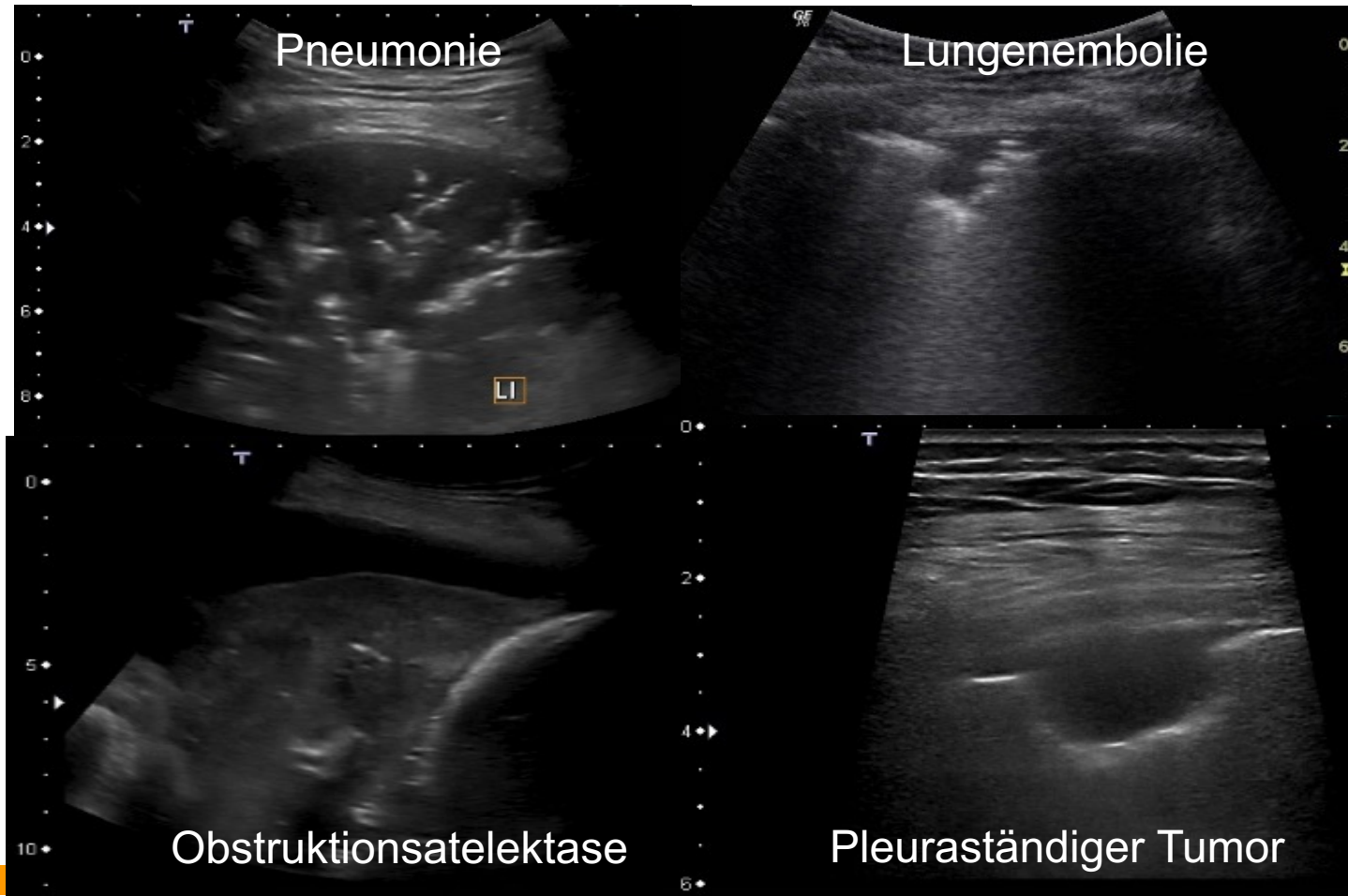
Thieme

Role of Contrast-Enhanced Ultrasound (CEUS) in Paediatric Practice: An EFSUMB Position Statement

The EFSUMB Guidelines and Recommendations for the Clinical Practice of Contrast-Enhanced Ultrasound (CEUS) in Non-Hepatic Applications: Update 2017 (Long Version)

Die EFSUMB-Leitlinien und Empfehlungen für den klinischen Einsatz des kontrastverstärkten Ultraschalls (CEUS) bei nicht-hepatischen Anwendungen: Update 2017 (Langversion)

Authors

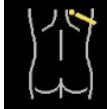
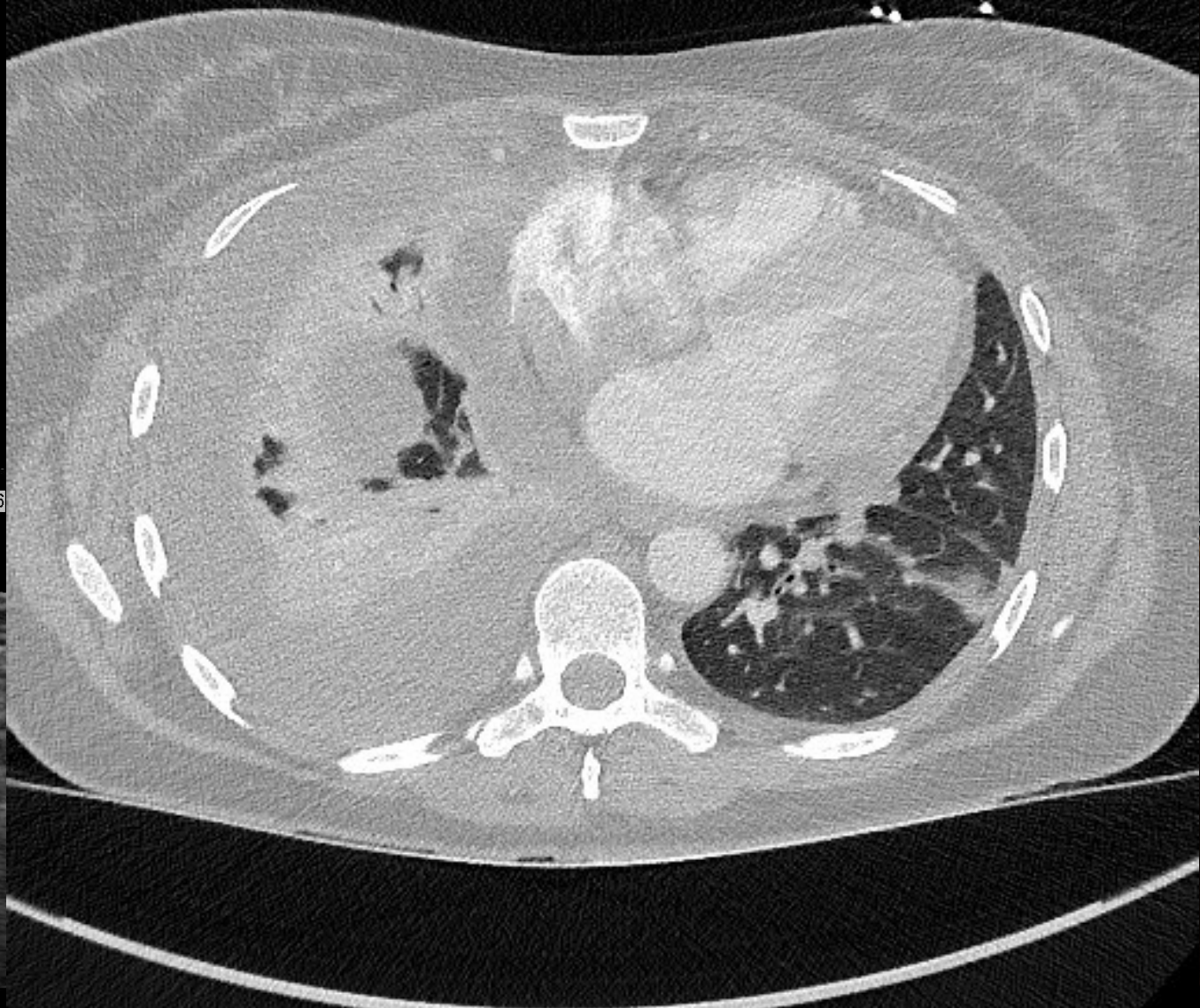
Differenzierung Konsolidierungen¹³

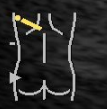Genese	entzündlich	Lungeninfarkt	Atelektase	neoplastisch
typisch	Echoarme Konturunterbrechung des echoreichen Pleurareflexbandes mit Darstellung einer echoarmen subpleuralen Lungenläsion			
Spezifische Charakteristika				
Form	unscharf begrenzt	rund (eher frisch) bis keilförmig (alt)	KA: bikonkav OA: weniger konkav, oft irregulär	oft scharf begrenzt, rund/ polyzyklisch, ggf. Invasivität
Größe	Klein subpleural bis lobär	≥ 2 Läsionen 0,5- 3 cm	KA: abh. v. Erguss OA: nach Höhe der Obstruktion	variabel
Bronchien	(dynam.) Aero-/ Fluidobronchogramm	Kaum Broncho-aerogramme	KA: +/- dynamisch OA: oft Fluidobronchogramm	--
Durchblutung (Duplex)	+	-/+ (teils frühe Reperfusion)	+	+/- irregulär
Kontrastierung im CEUS	+ früh, homogen	- spät, nur peripher	+ früh, homogen	+/- spät, inhomogen



TrC-2.0Rx
R:13.0
BG:69
BD:72



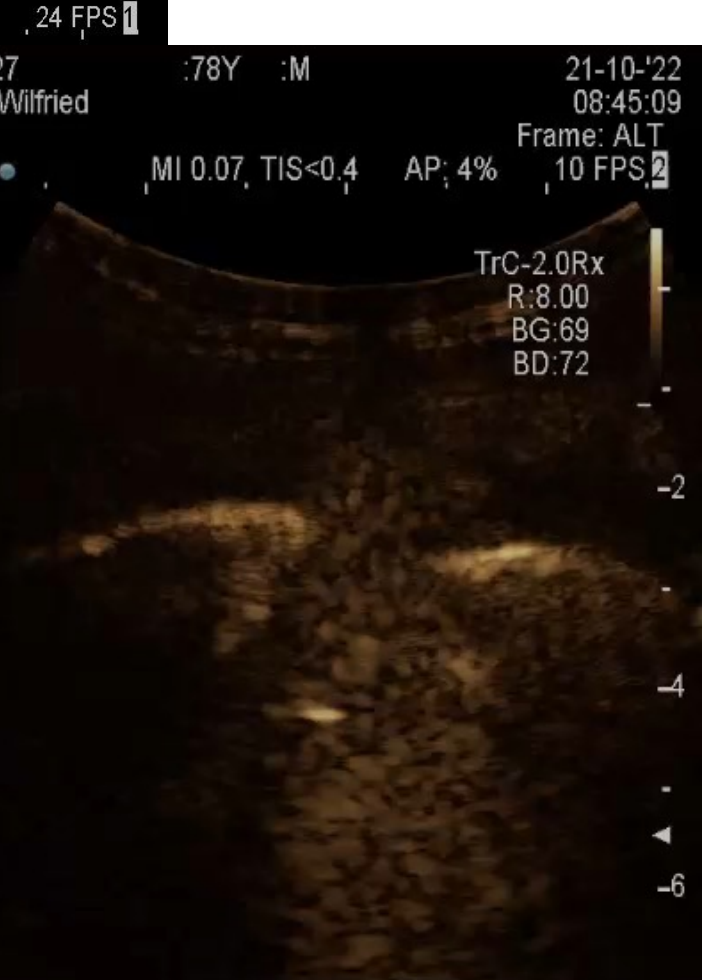
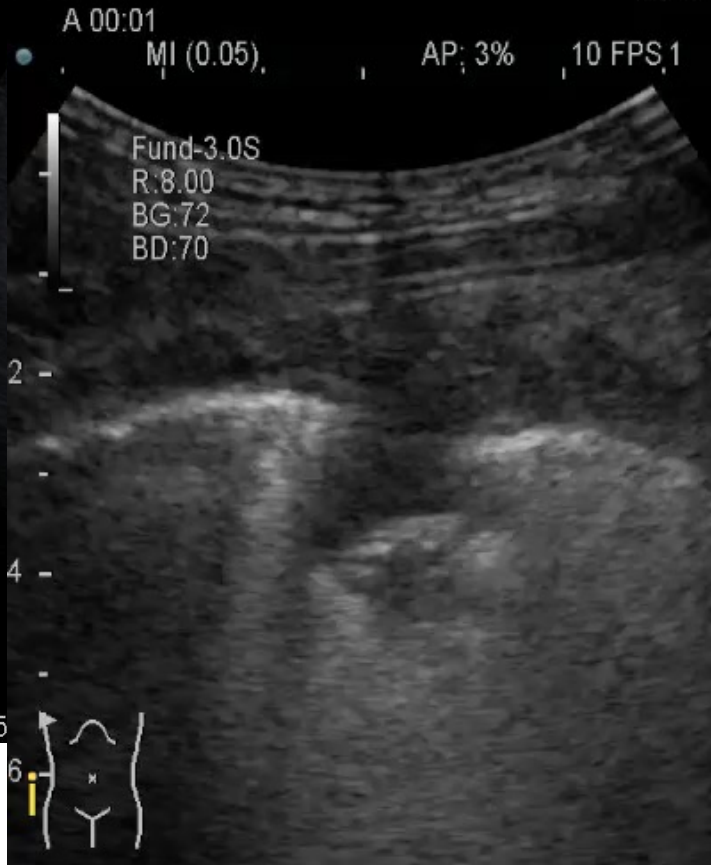H Abdomen C251
ALOKA
A 00:33 00:36
MI (0.05)
Fund-3.0S
R:7.00
BG:72
BD:70



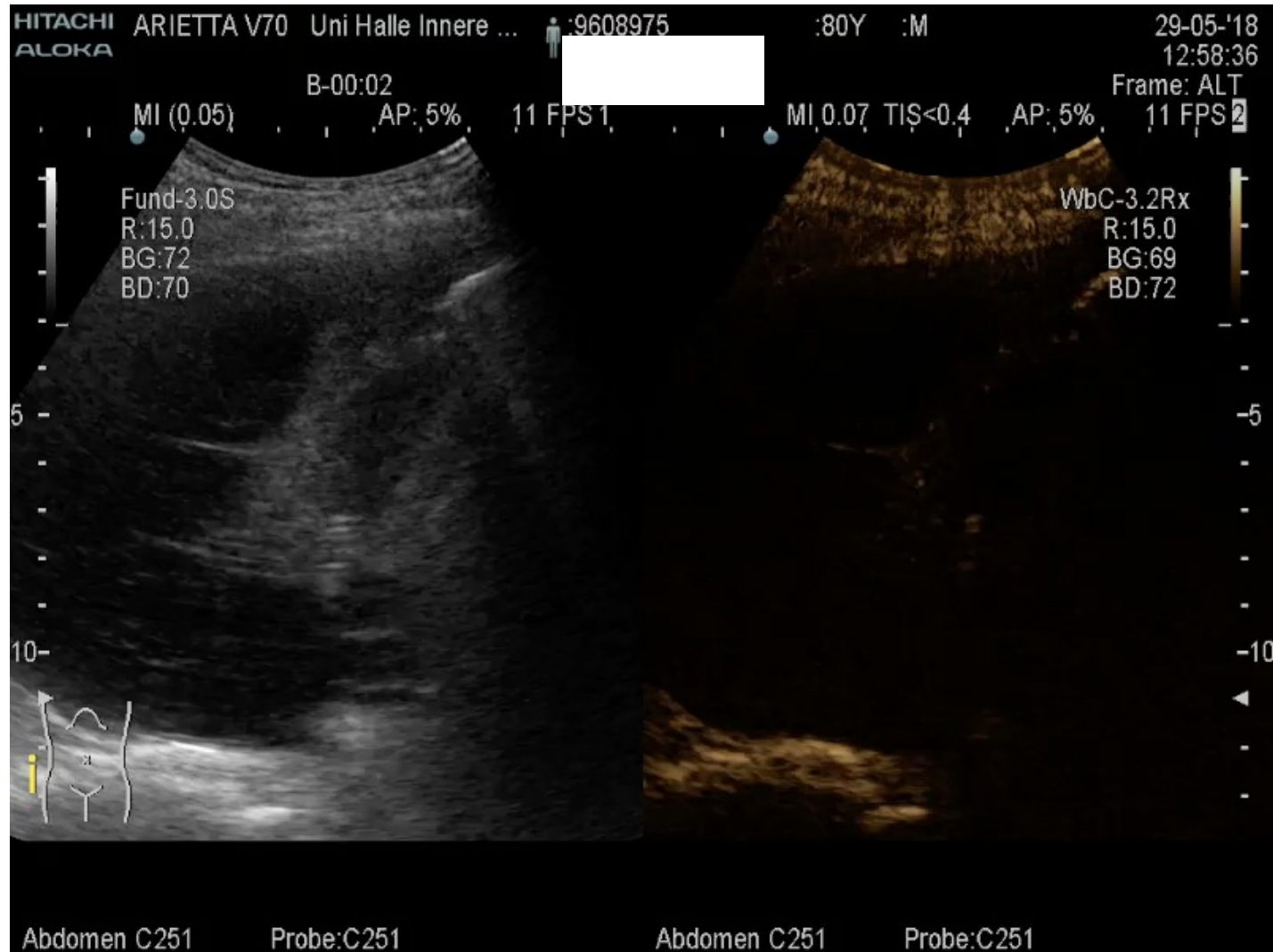
TrC-2.0Rx
R:13.0
BG:69
BD:72

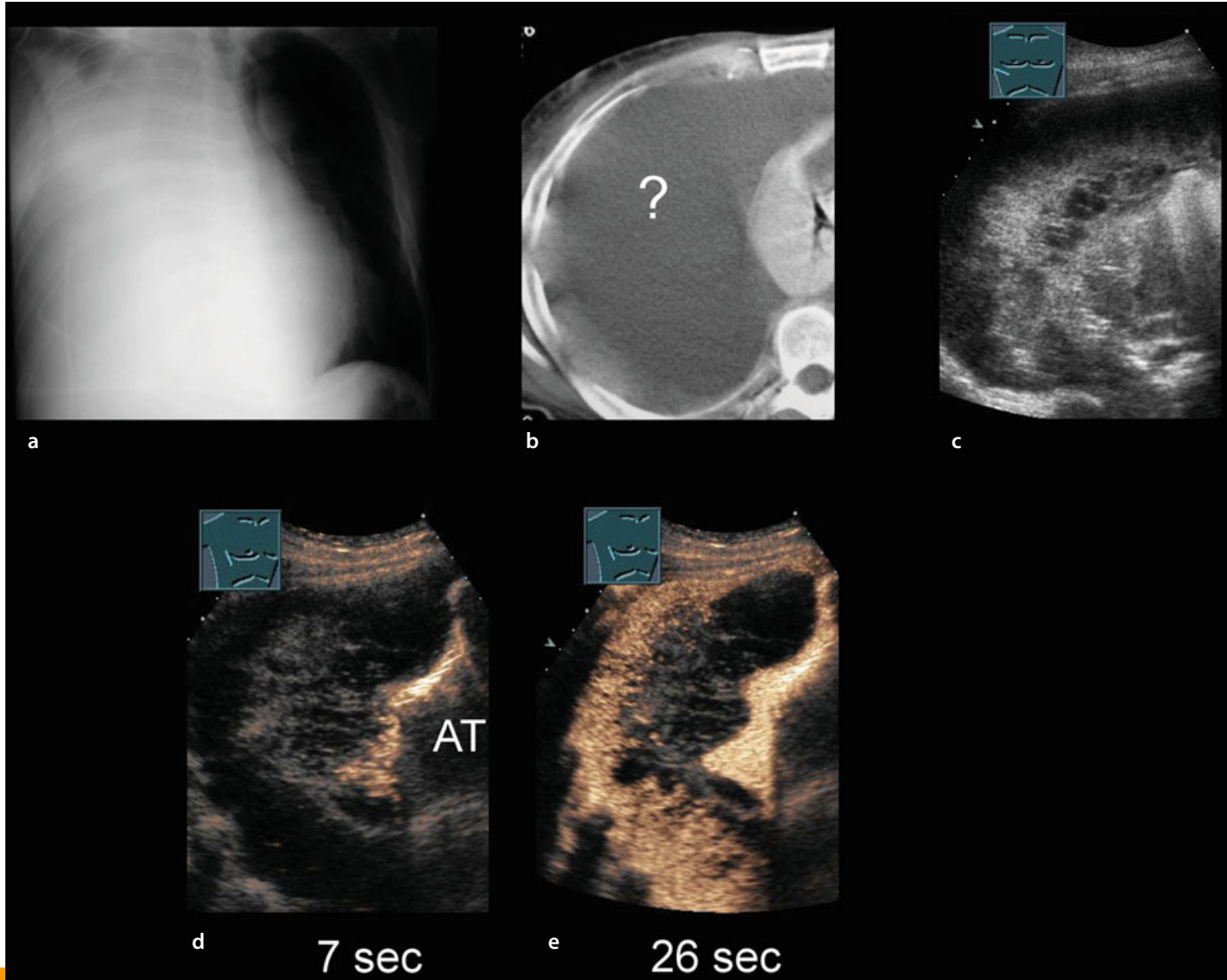
HITACHI ARIETTA V70 Uni Halle Innere ... :6017627 :78Y :M 21-10-'22 08:40:25
ALOKA :Wölfel Wilfried

HITACHI ARIETTA V70 Uni Halle Innere ... :6017627 :78Y :M 21-10-'22 08:45:09
ALOKA :Wölfel Wilfried



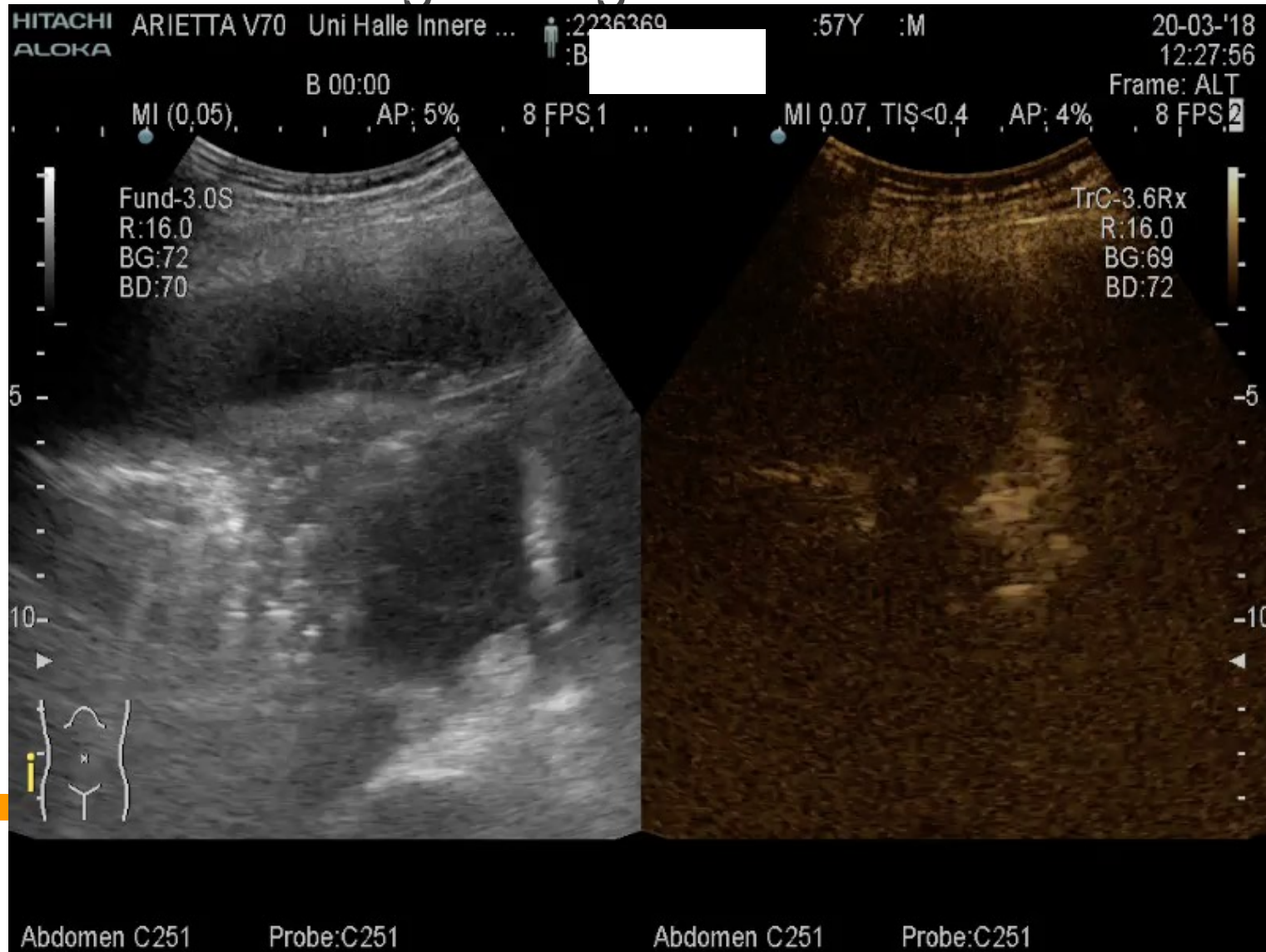
Abgrenzung pleuraler Strukturen vs. gefesselte Lunge





Mit freundlicher Genehmigung C. Goerg/Marburg

Unterscheidung flüssig vs. solide



Contrast-enhanced ultrasound does not discriminate between community acquired pneumonia and lung cancer

Marco Sperandeo¹, Gaetano Rea², Maria Arcangela Grimaldi³, Francesca Trovato⁴, Lucia M C Dimitri⁵, Vincenzo Carnevale³

[Author affiliations](#) +

Abstract

We investigated if contrast-enhanced ultrasound (CEUS) may differentiate community acquired pneumonia (CAP) from lung cancer (LC). Among 1374 patients admitted in a 5-year period for lung opacities, 728 (329 CAP and 399 LC) were investigated by CEUS, comparing the time of appearance, disappearance, duration and pattern of distribution of contrast enhancement (CE). The patients with CAP and LC did not differ in terms of age, time of CE appearance, disappearance and duration or CE distribution. Our data show that the timing and pattern of CE detected by chest CEUS does not distinguish between CAP and LC and overly optimistic beliefs on this matter should be abandoned.



Prospektive Untersuchung n=110

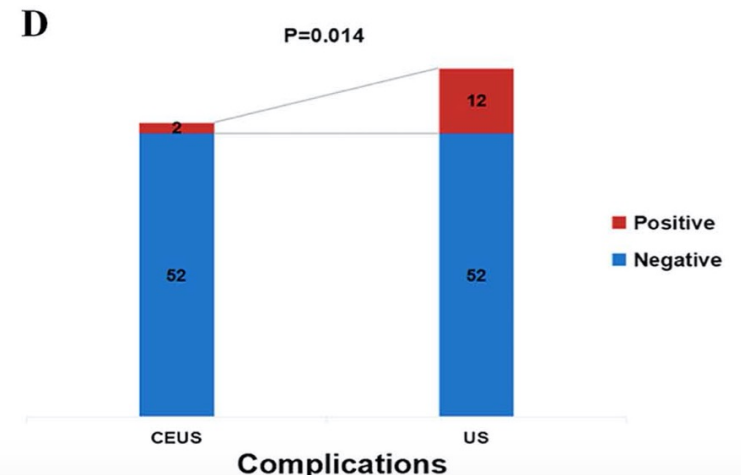
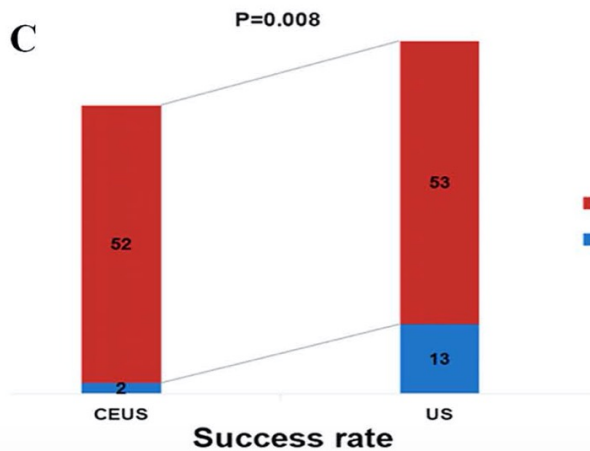
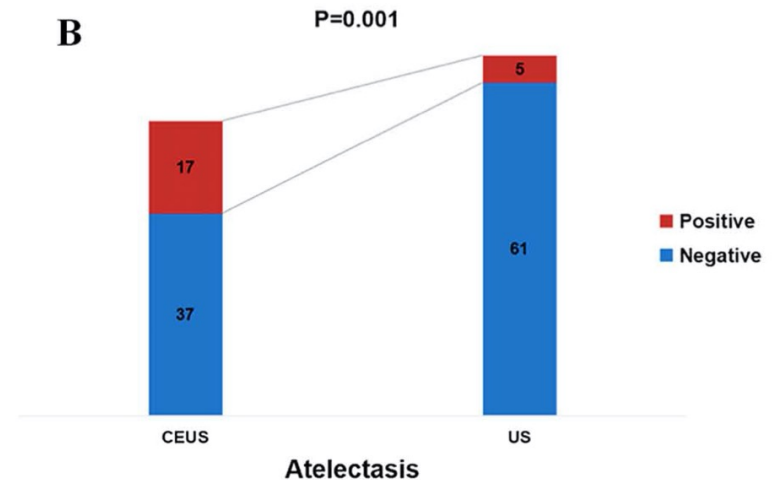
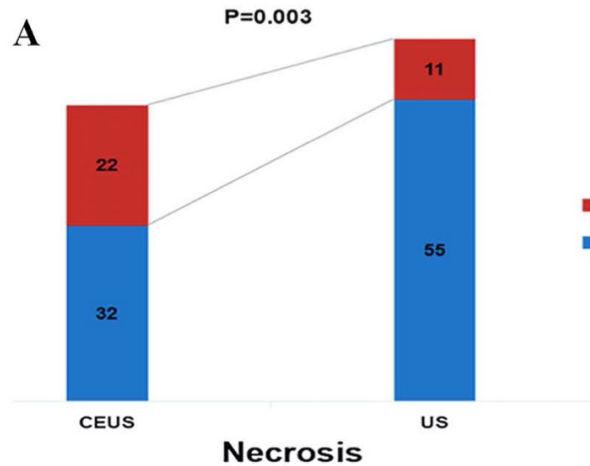


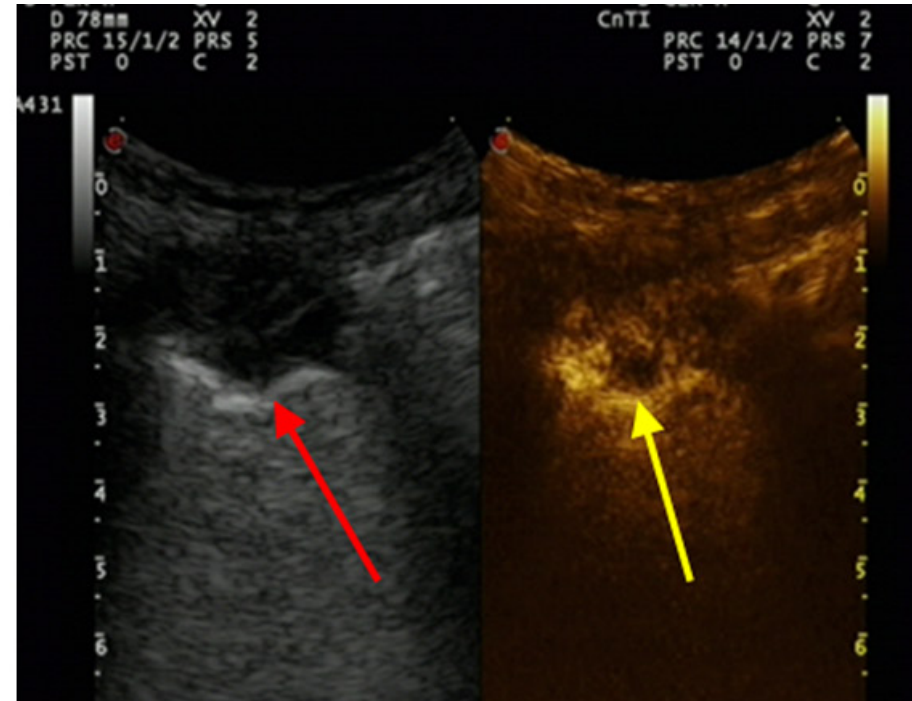
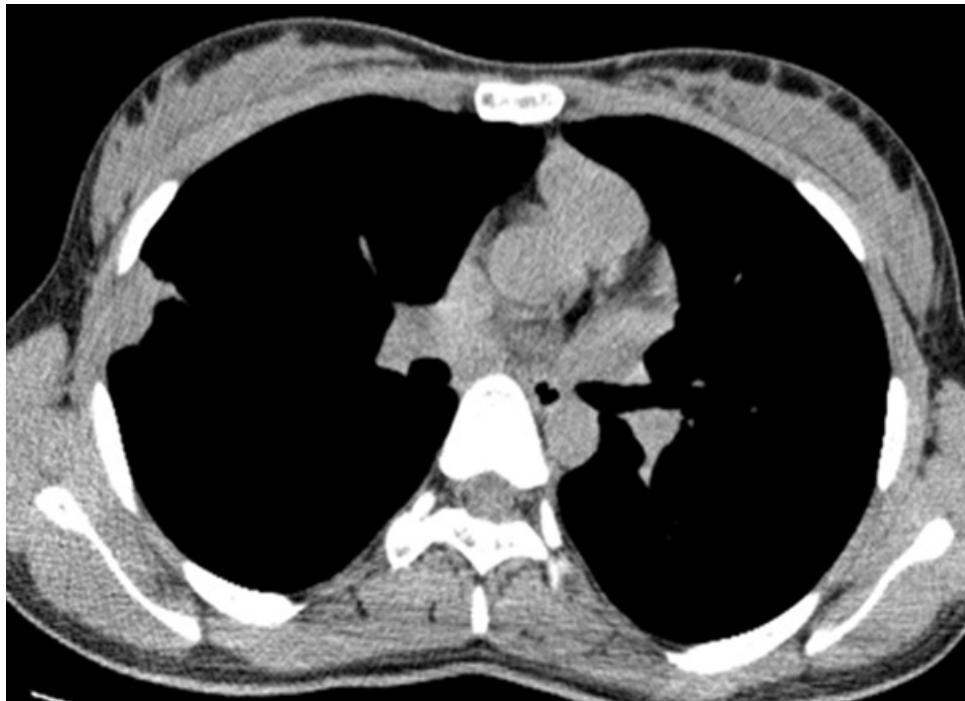Table II. Comp

Characteristics

- Size, cm
- Necrosis, % (n/
- Atelectasis, % (
- Punctures time:
- Success rate, %
- Complications,



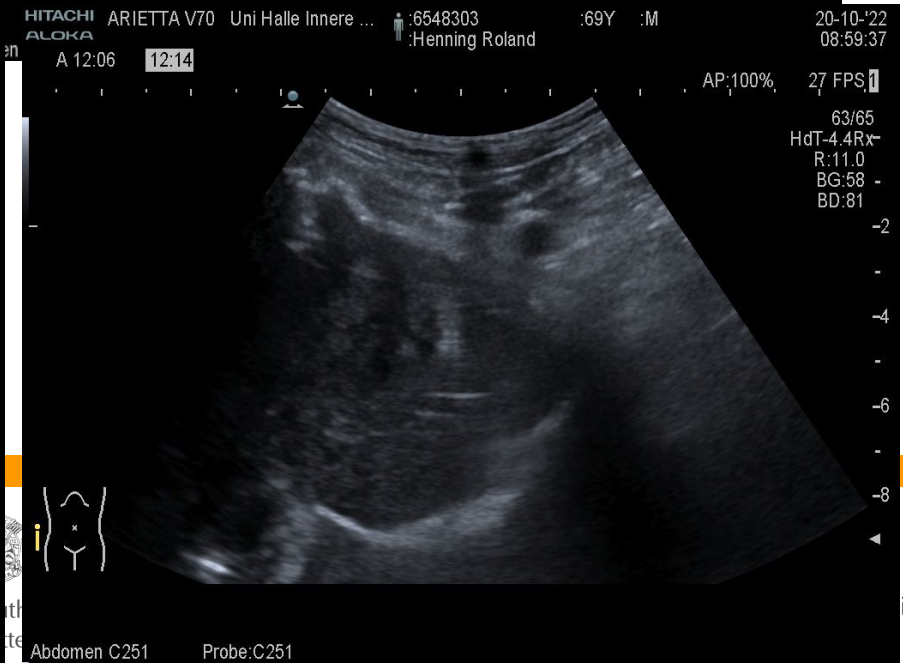
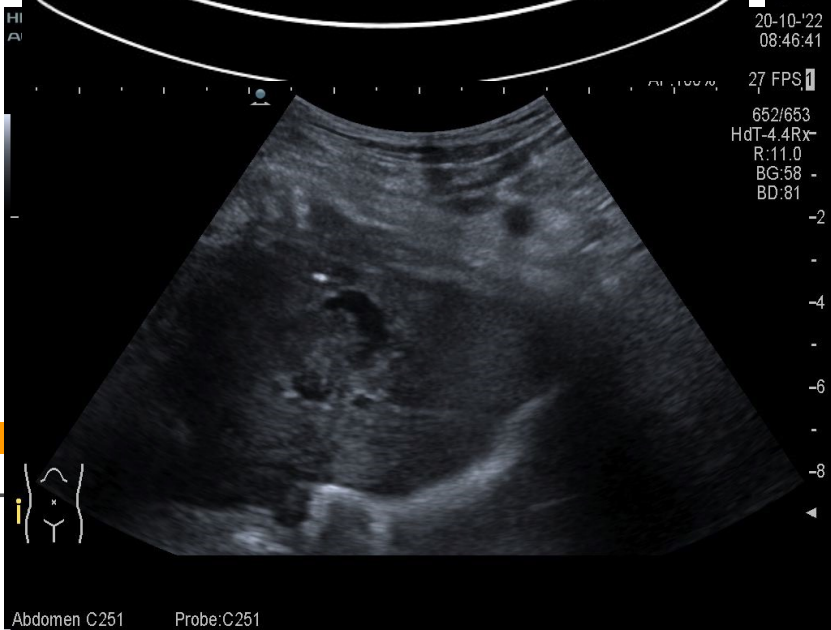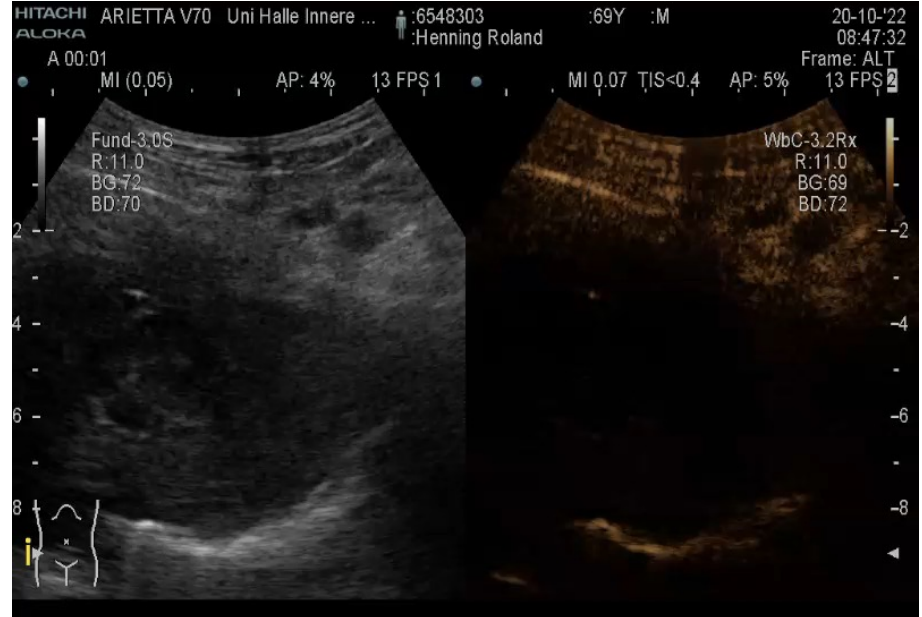
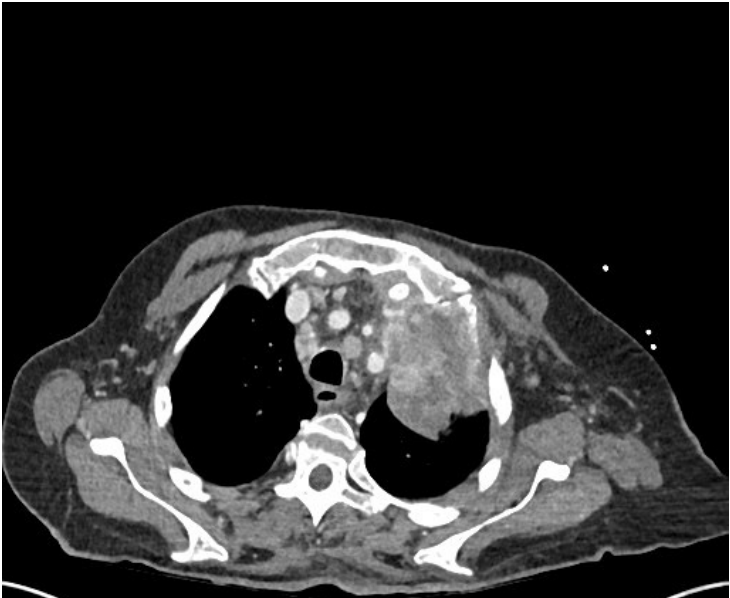
Peripherer Tumor zur Biopsie



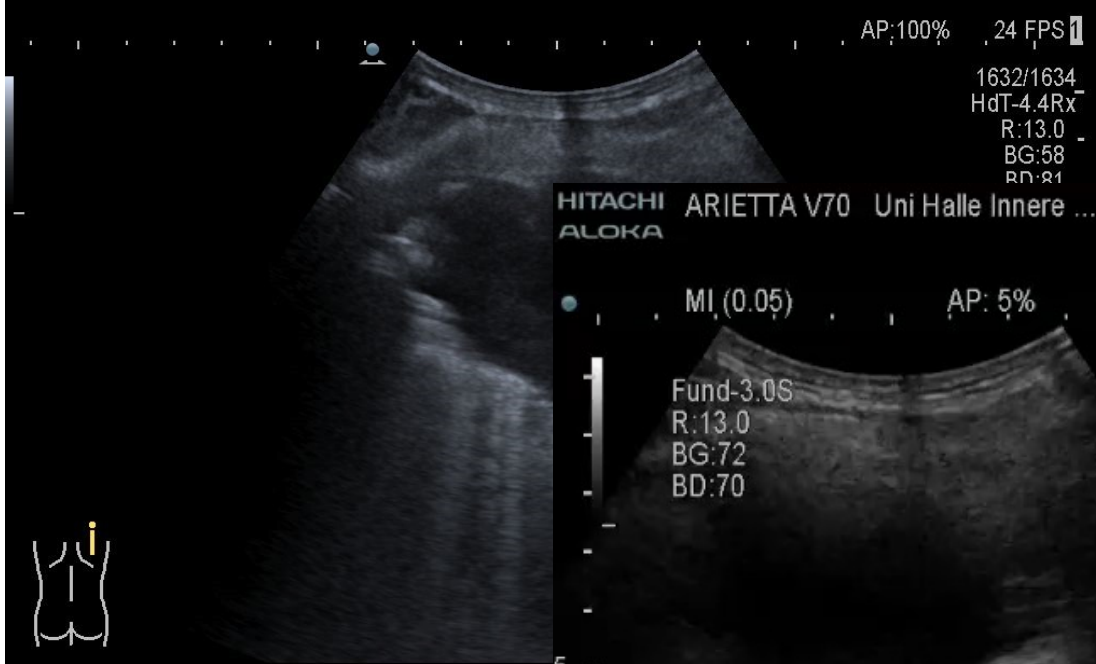Martin-Luther-Universität
Halle-Wittenberg



Universitätsklinikum
Halle (Saale)

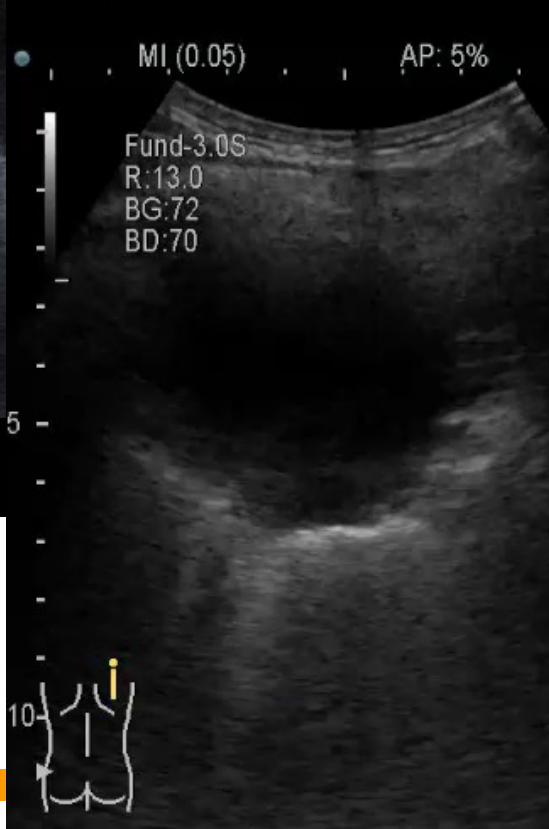


HITACHI ARIETTA V70 Uni Halle Innere ... :6548642 :85Y :M 21-10-'22
ALOKA :Schmeißer Hans-Jochen 09:39:26



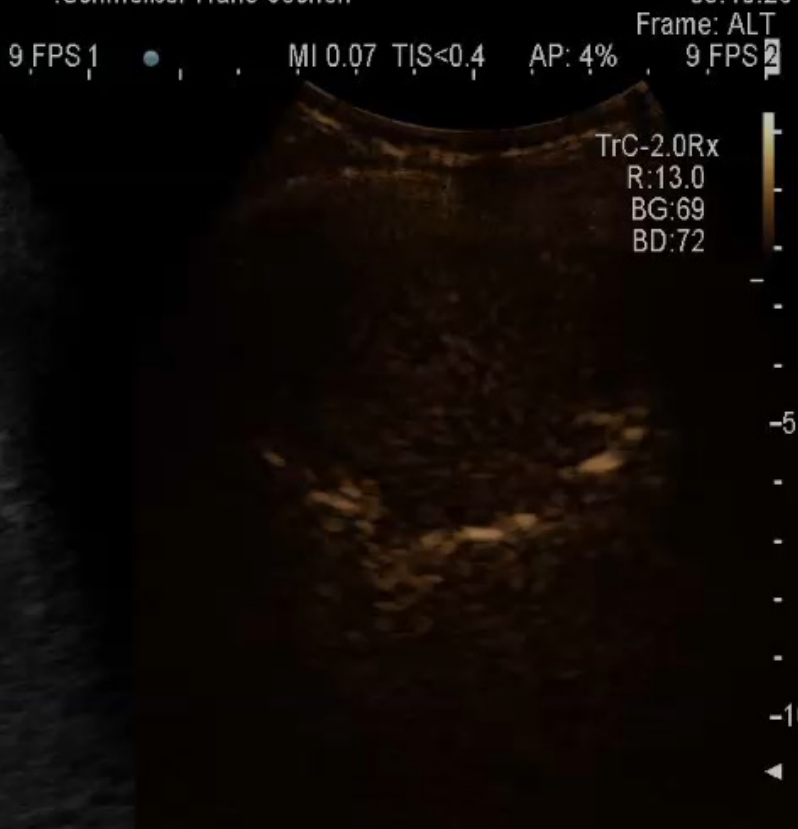
Abdomen C251 Probe:C251

HITACHI ARIETTA V70 Uni Halle Innere ... :6548642 :85Y :M 21-10-'22
ALOKA :Schmeißer Hans-Jochen 09:40:26

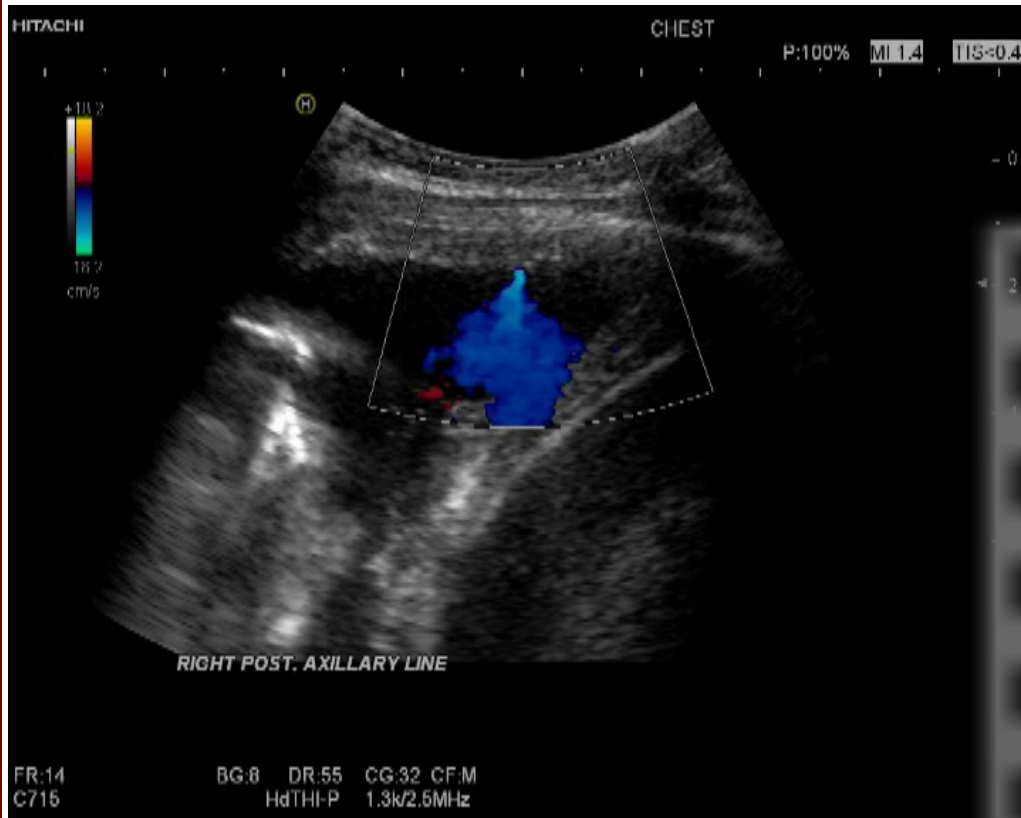


Abdomen C251 Probe:C251

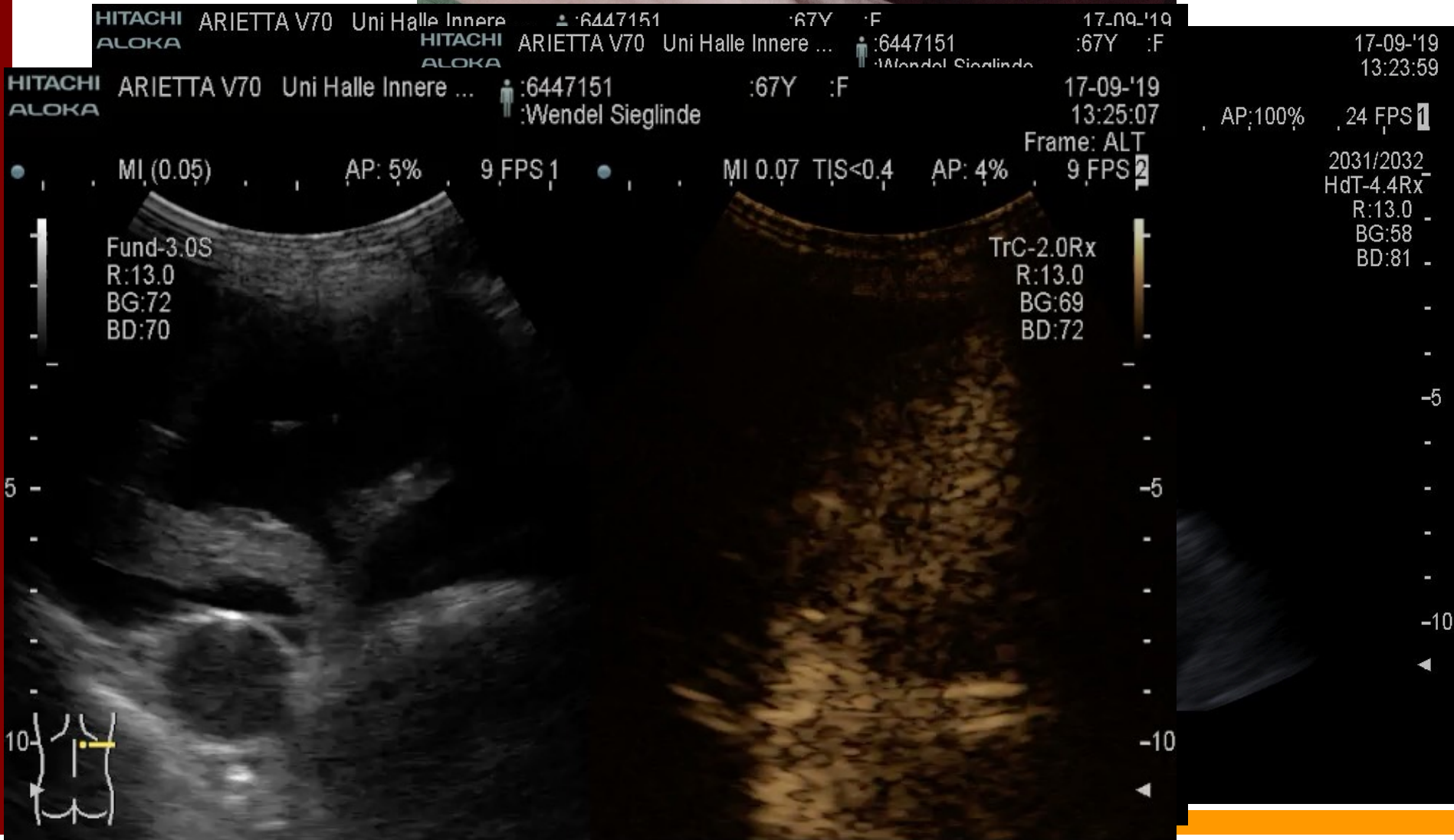HITACHI ARIETTA V70 Uni Halle Innere ... :6548642 :85Y :M 21-10-'22
ALOKA :Schmeißer Hans-Jochen 09:40:26



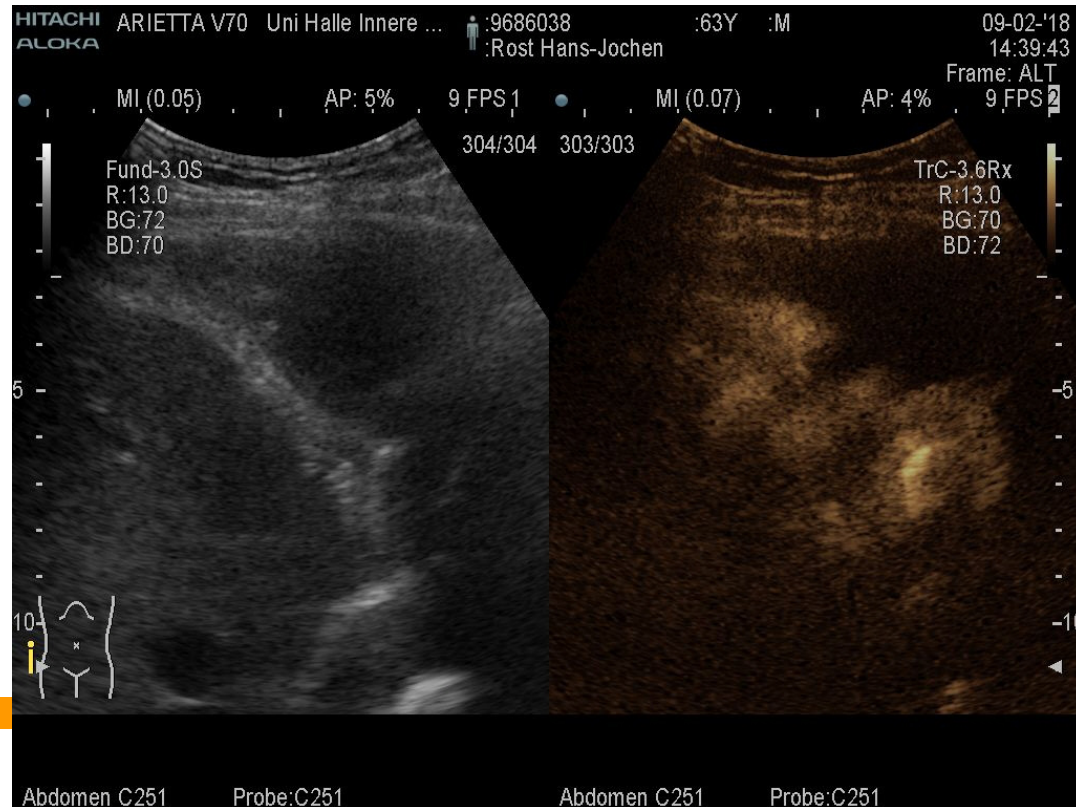
Abdomen C251 Probe:C251

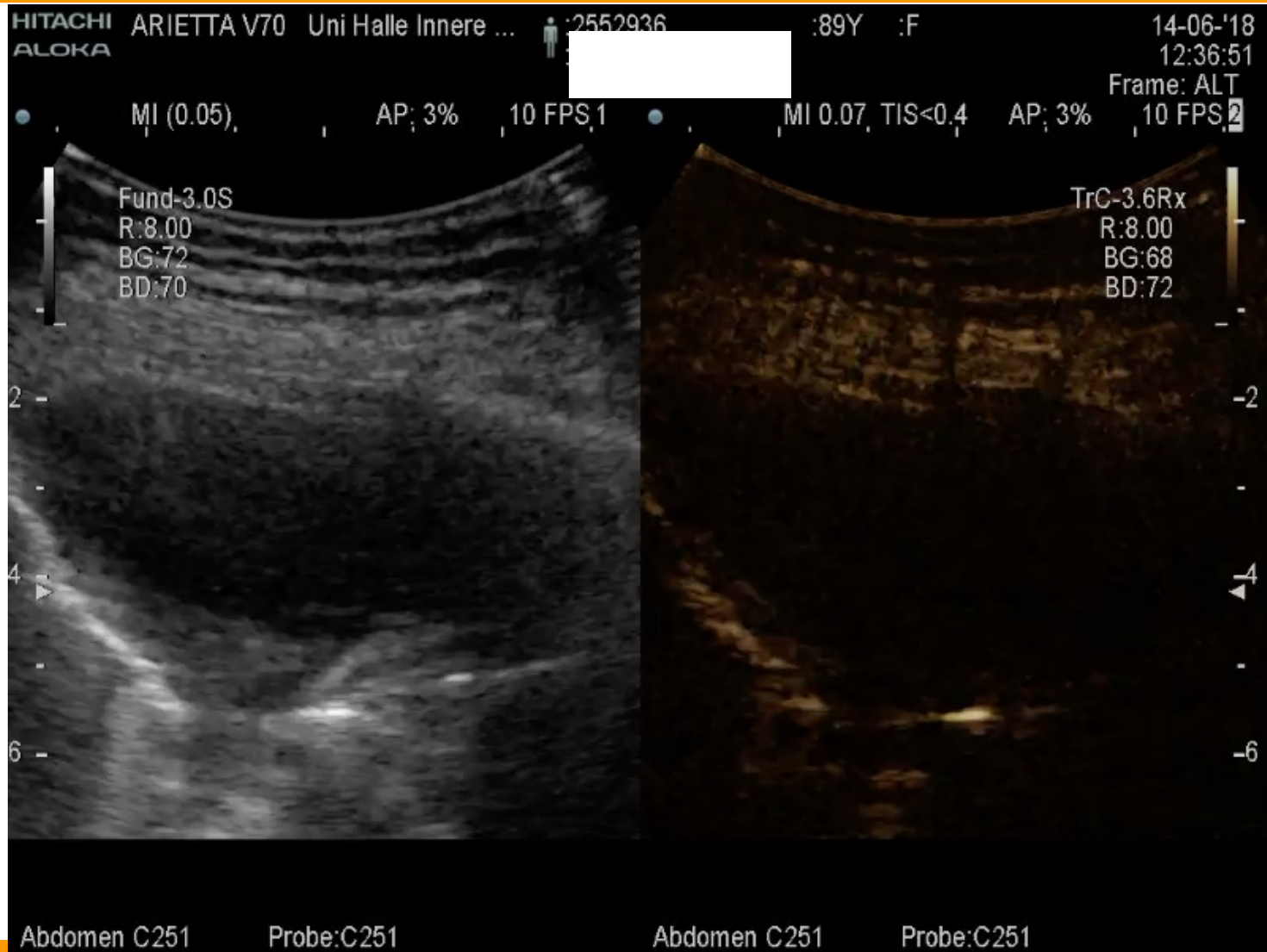


Komplikation ? Blutiger Erguss

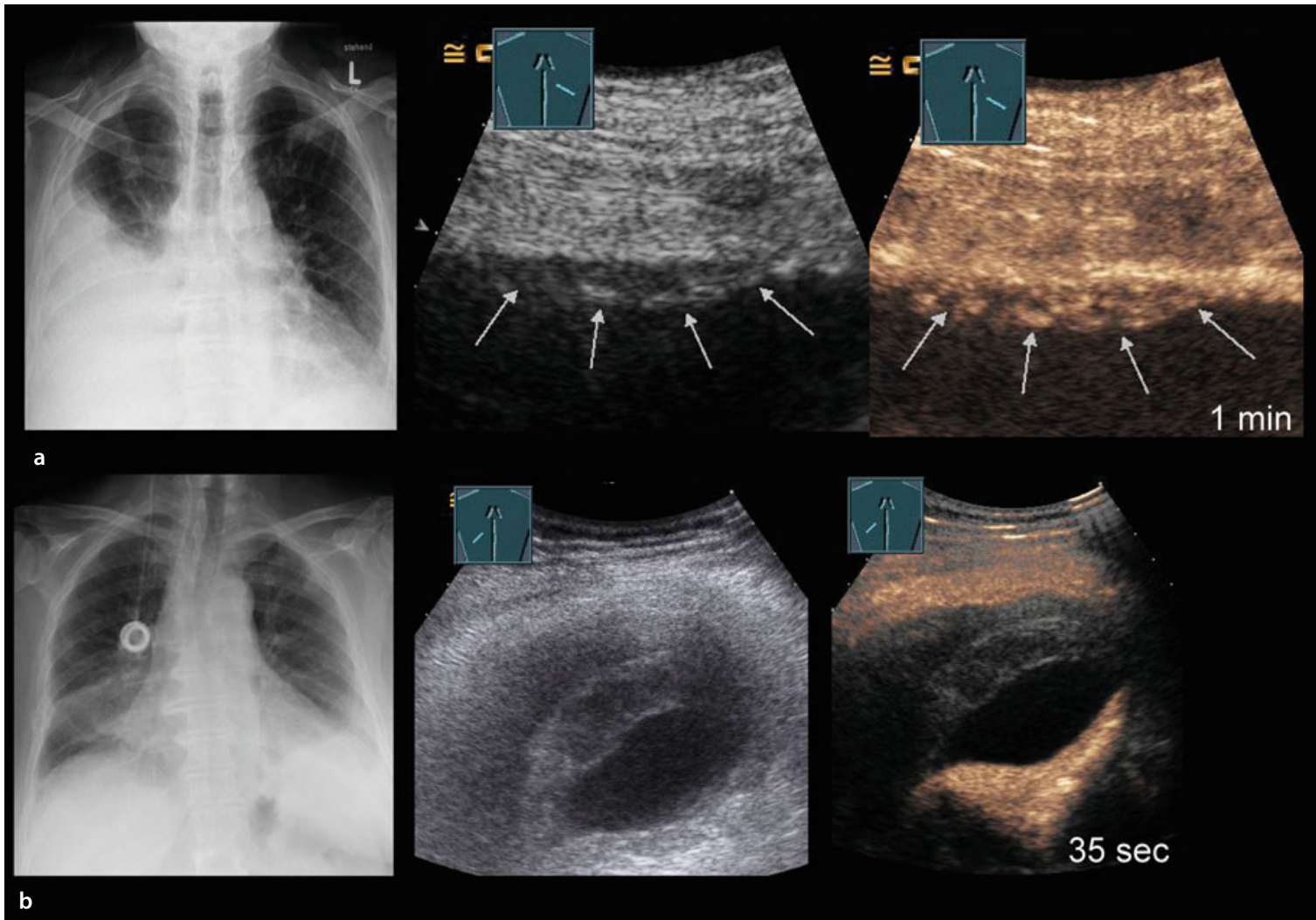


Differentierung Erguss vs. Tumour Differentierung pleuraständiger Herde Drainagemanagement





Pleurakarzinose vs. Fibrin



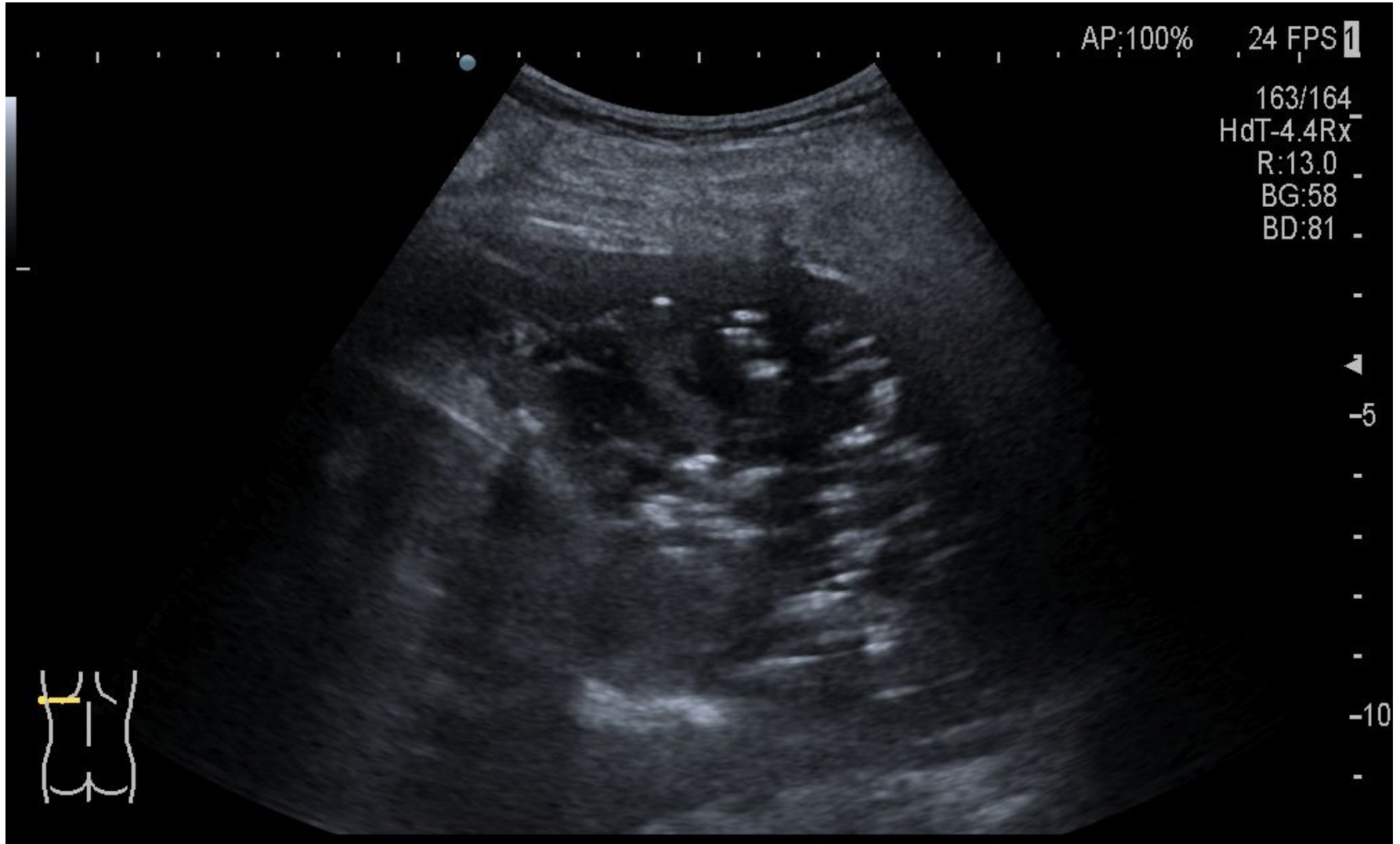Mit freundlicher Genehmigung C. Goerg/Marburg

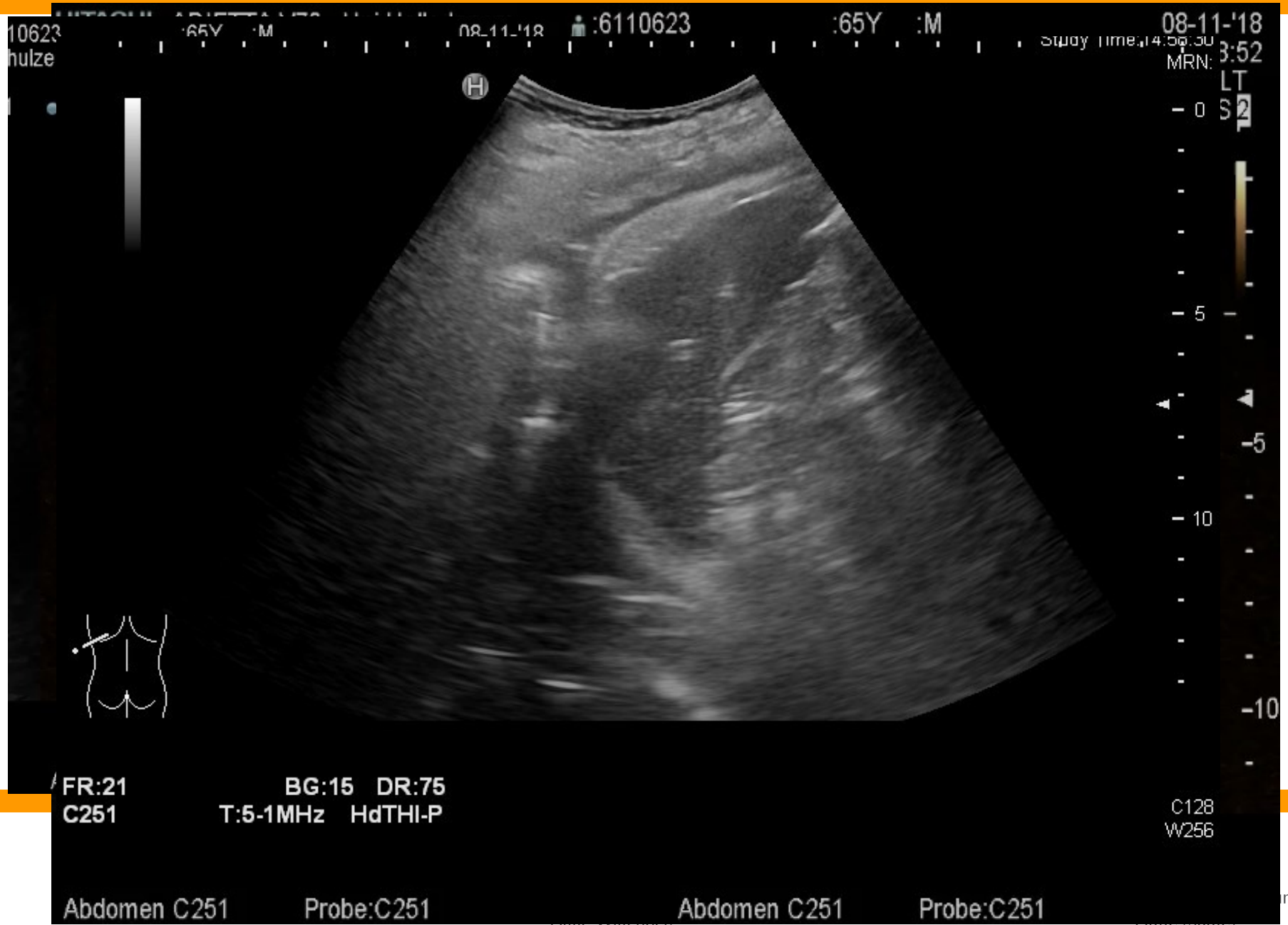

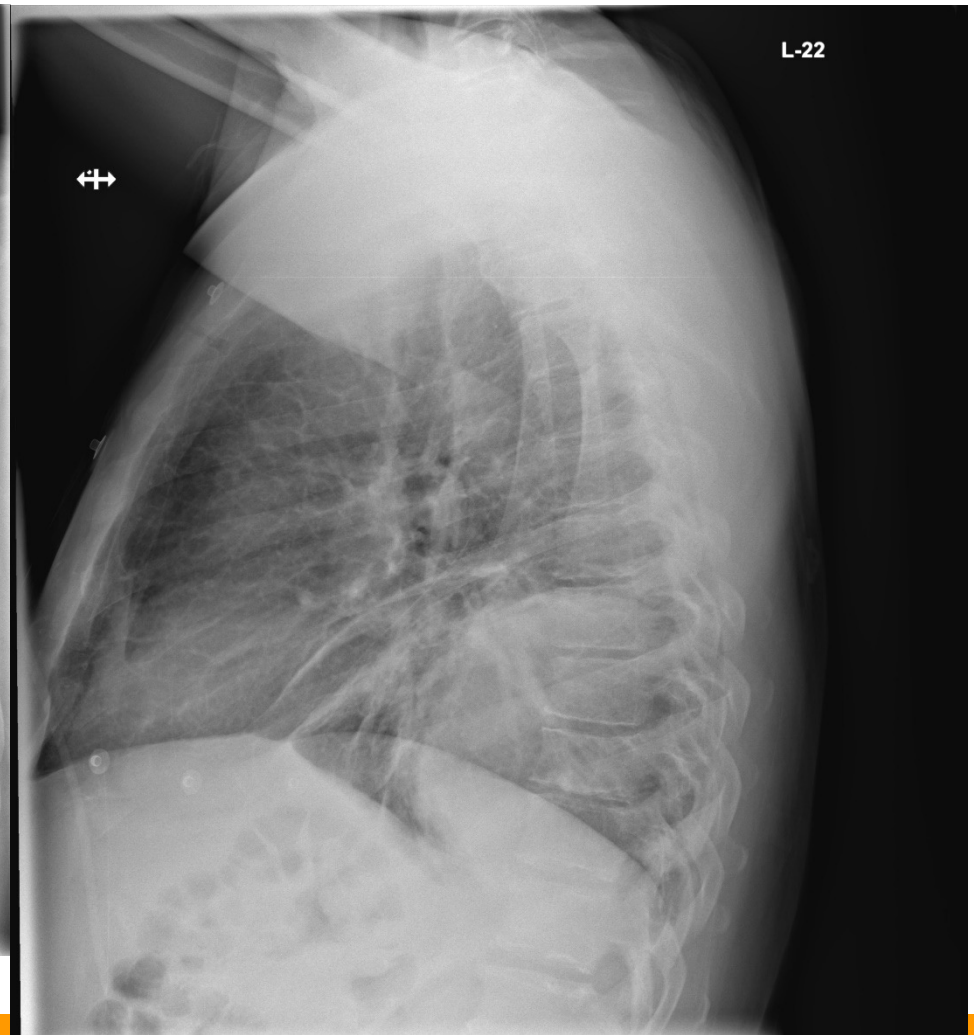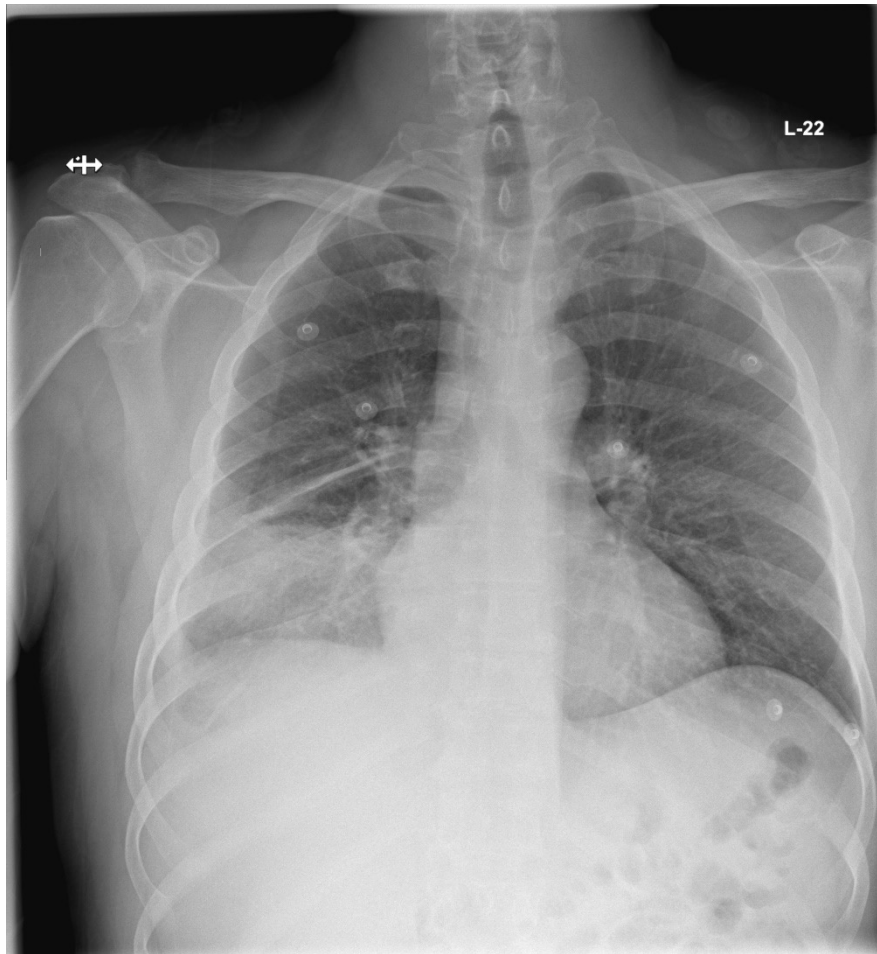
Martin-Luther-Universität
Halle-Wittenberg



Universitätsklinikum
Halle (Saale)



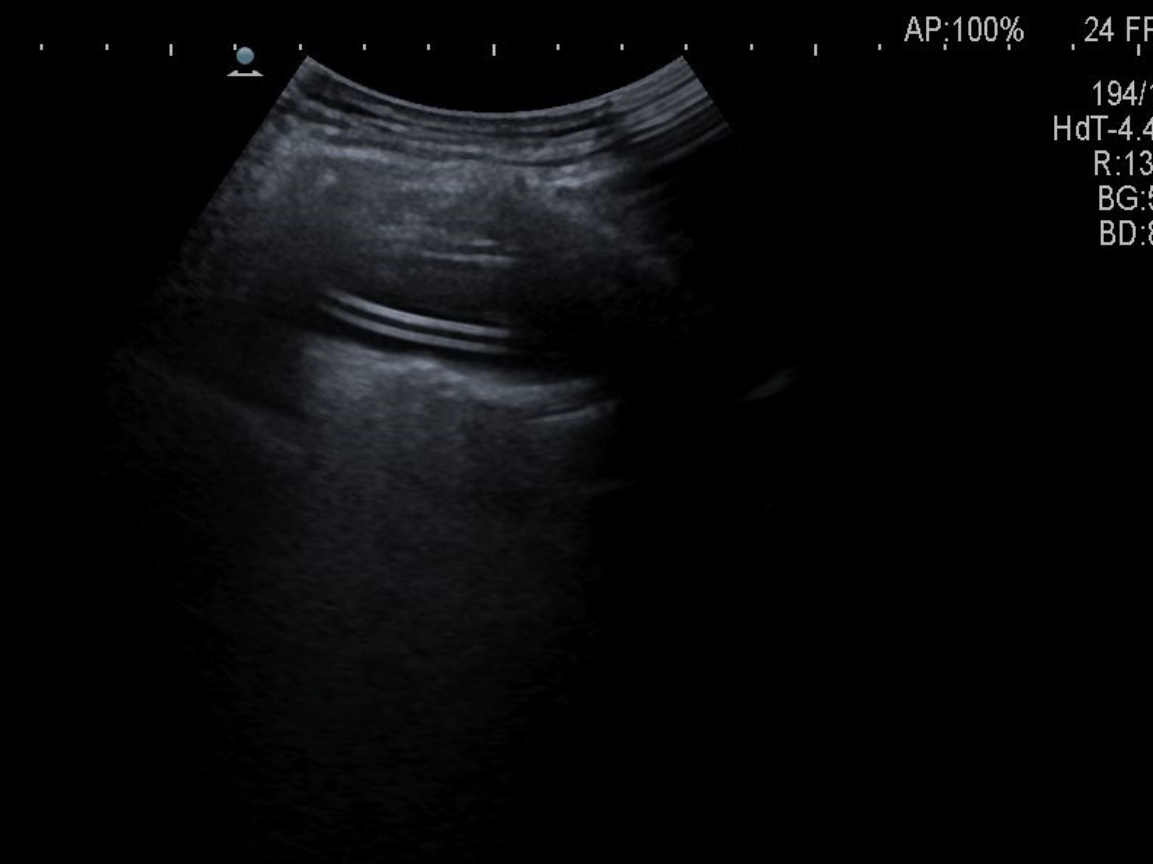




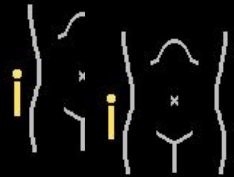HITACHI ARIETTA V70 Uni Halle Innere ... :6100820 :48Y :M 20-09-'21
 ALOKA
 HITACHI ARIETTA V70 Uni Halle Innere [redacted] :48Y :M 20-09-'21
 ALOKA 13:21:51

AP:100% 24 FPS 1
 194/195
 HdT-4.4Rx
 R:13.0
 BG:57
 BD:81

-5
 -10



Abdomen C251 Probe:C251



1200 Patienten, Stopp des Drainageflusses 24 h nach Katheteranlage (16 G)

Einschluss: 304 Patienten (Ergussmenge mind. 100 ml)

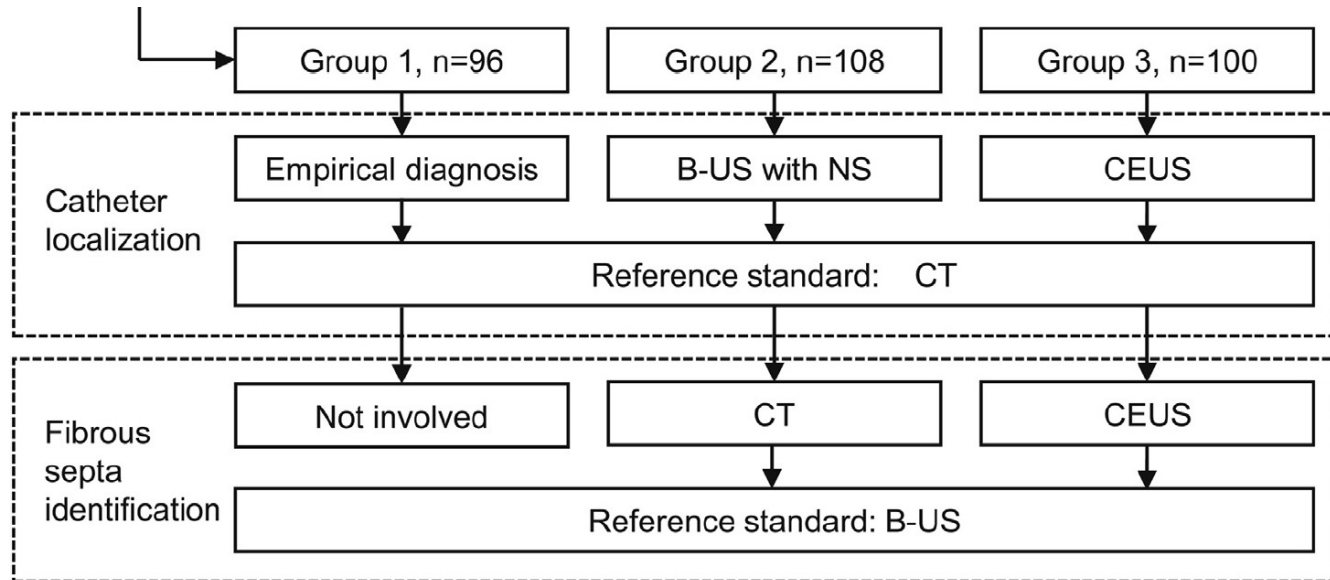


Table 2. Catheter-localization performance

Performance		Empirical diagnosis (group 1)	B-US (group 2)	CEUS (group 3)
Reference standard: CT	TP/FN	40/20	40/24	64/0
	FP/TN	24/12	0/44	0/36
Accuracy		54.17 (43.69–64.38)	77.78 (68.76–85.21)	100 (96.38–100)
Sensitivity		66.67 (53.21–77.98)	62.50 (49.47–74.02)	100 (92.95–100)
Specificity		33.33 (19.1–51.05)	100 (90–100)	100 (87.99–100)
PPV		62.50 (49.47–74.02)	100 (89.09–100)	100 (92.95–100)
NPV		37.50 (21.66–56.25)	61.76 (52.1–75.64)	100 (87.99–100)

Values are given as percentage (95% confidence interval).

B-US = B-mode ultrasound; CEUS = contrast-enhanced ultrasound; FN = false negative; FP = false positive; NPV = negative predictive value; PPV = positive predictive value; TN = true negative; TP = true positive.

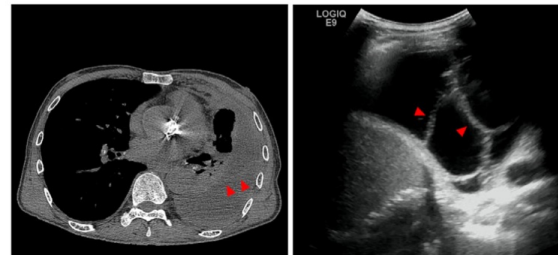
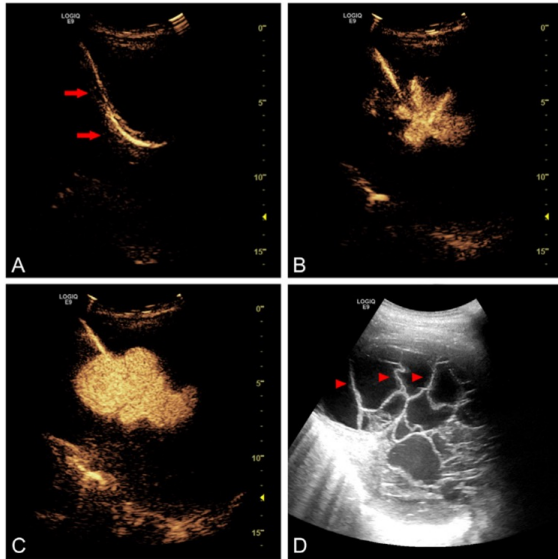


Table 3. Fibrous-septa identification performance

Performance		CT (group 2)	CEUS (group 3)
Reference standard:	TP/FN	6/17	27/0
B-US	FP/TN	2/83	0/73
Accuracy		82.41 (73.9–89.06)	100 (96.38–100)
Sensitivity		26.09 (11.08–48.69)	100 (84.5–100)
Specificity		97.65 (90.96–99.59)	100 (93.77–100)
PPV		75 (35.58–95.55)	100 (84.5–100)
NPV		83 (73.89–89.51)	100 (93.77–100)

Values are given as percentage (95% confidence interval).

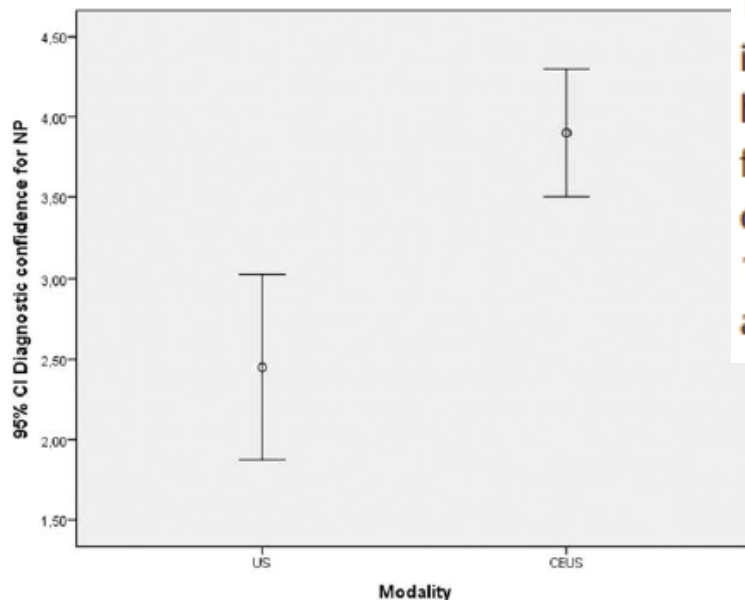
B-US = B-mode ultrasound; CEUS = contrast-enhanced ultrasound; FN = false negative; FP = false positive; NPV = negative predictive value; PPV = positive predictive value; TN = true negative; TP = true positive.

Intravenous and Intracavitary Use of Contrast-Enhanced Ultrasound in the Evaluation and Management of Complicated Pediatric Pneumonia

Figure 7. Error bar graph showing the diagnostic confidence values for diagnosing necrotizing pneumonia (NP) using grayscale US and contrast-enhanced US (CEUS; $P < .001$). CI indicates confidence interval.

Obstetrics

The use of UCA in obstetrics is not indicated as there has been limited research related to the uncertainty of a possible underlying harmful effect. No recent human or animal studies have been performed. It is unknown whether the UCA passes through the placenta, though this seems unlikely as previously suggested [125, 126]. CEUS to assess a pregnant mother should be balanced against the risk of other imaging modalities.



CEUS in Leisten-Lymphknoten, Kontrolle Pleura und Venenwinkel links

JVIR
Journal of Vascular and Interventional Radiology

Society of
Interventional
Radiology

SIR Member Login Log in Register Subscribe Claim 🔍 ☰

BRIEF REPORT | VOLUME 31, ISSUE 10, P1670-1674, OCTOBER 01, 2020

Purchase Subscribe Save Share Reprints Request

Use of Contrast-Enhanced Ultrasound to Determine Thoracic Duct Patency

Erika J. Mejia, MD • Hansel J. Otero, MD • Christopher L. Smith, MD, PhD • ... Jonathan J. Rome, MD •
Yoav Dori, MD, PhD • David M. Biko, MD • [Show all authors](#)

Published: September 09, 2020 • DOI: <https://doi.org/10.1016/j.jvir.2020.05.022> • Check for updates

PlumX Metrics





9-10. März 2023

THORAXSONOGRAPHIE

KURS NACH DEN RICHTLINIEN DER DEGUM

Schirmherr:

Deutsche Gesellschaft für Pneumologie und
Beatmungsmedizin e.V.

Wissenschaftliche Leitung:

Dr. Stephan Eisenmann
Universitätsklinikum Halle (Saale)

pneumologie@uk-halle.de



Martin-Luther-Universität
Halle-Wittenberg



Universitätsklinikum
Halle (Saale)